

Alveolar Ridge Regeneration of Damaged Extraction Sockets using a Bovine-derived Bone Graft in Association with a Titanium Foil: Prospective Case Series

Danilo Maeda¹, Fernando Lima², Jonathan Meza², Danilo Lazzari Ciotti³, Fabio Shiniti Mizutani¹, Helio Doyle², Marcelo Faveri²

¹Private practice. ²Department of Periodontology, Dental Research Division, Guarulhos University, Guarulhos, SP, Brazil.

³Department of Periodontology, São Leopoldo Mandic University, Brazil

Abstract

Aims: This study aimed to determine the dimensional change in the alveolar ridge after using an anodized titanium foil (Tseal) in association with bovine bone (BB) grafting in damaged extraction sockets by cone-beam computerized-tomography.

Materials and Methods: Fifteen patients who had one hopeless tooth with over 80% of the buccal wall lost were selected and then the teeth were carefully extracted. The alveolar socket was filled with bovine bone and the Tseal was trimmed and adapted over the bone crest. The primary outcome variable was the change in the alveolar dimension (AD) measurements between baseline (T1) and 6 months (T2) after extraction in three points of analysis, 1mm, 3mm and 5mm below the palatal bone crest.

Results: Bone regeneration was observed to occur between 87% and 116% of the AD assessed at the baseline. No statistical differences were observed. The mean AD value varied from 7.82 ± 2.75 mm (T1) to 8.02 ± 2.43 mm (T2) in the 1 mm point, from 7.99 ± 2.67 mm to 8.71 ± 2.26 mm to 3 mm and 8.56 ± 2.60 mm to 9.00 ± 2.52 mm at 5 mm area.

Conclusion: Bovine bone graft in association with Tseal achieved horizontal reconstruction of the alveolar crest in compromised socket within 6 months after surgery.

Keywords: Bone augmentation, bone regeneration, titanium membrane, bone graft.

Introduction

Tooth extraction is one of the most widely performed dental procedures. After tooth extraction, soft tissue and alveolar bone healing are characterized by remodeling and reabsorption processes (Amler, 1969; Cardaropoli *et al.*, 2003; Araujo and Lindhe, 2005; Ten Heggeler *et al.*, 2011) that occurs over a few weeks. The major remodelling of an extraction site takes place during the first year, with 2/3 of these changes occurring in the first

three months post-surgery (Schropp *et al.*, 2003). The width of the alveolar ridge may be reduced up to 50% during the remodelling period, corresponding to 5 to 7 mm. In a systematic review evaluating the dimensional changes in the alveolar ridge after tooth extraction found a mean reduction of 3.8 mm in width and 1.24 mm in height within the first six months (Tan *et al.*, 2012). These changes can compromise the esthetic outcome of final restorations, either with implant placement or with traditional prosthetic procedures. Therefore, to minimize these changes, alveolar ridge preservation techniques have become a popular and are an important in guided bone regeneration (GBR) procedures. Several systematic reviews have confirmed the efficacy of different alveolar ridge preservation techniques to minimize post-extraction dimensional changes in alveolar ridges

Correspondance to: Marcelo Faveri, Centro de Pós-Graduação e Pesquisa-CEPPE, Universidade Guarulhos, Praça Tereza Cristina, 229 Centro, 07023-070 Guarulhos, SP, Brazil
e-mail: mdfaveri@uol.com.br

after tooth extraction (Horvath *et al.*, 2013; Vignoletti *et al.*, 2012; Vittorini *et al.*, 2013). Many materials have been studied including demineralized freeze-dried bone allograft (DFDBA) (Becker *et al.*, 1994; Froum *et al.*, 2002; Bianchini *et al.*, 2009; Beck and Mealey, 2010; Clark *et al.*, 2018) xenografts (Araujo and Lindhe, 2009b; Mardas *et al.*, 2010) alloplasts (Ashman, 2000; De Risi *et al.*, 2015) and PRF (Anwandter *et al.*, 2016; Temmerman *et al.*, 2016; Clark *et al.*, 2018). GBR (using a variety of barrier membrane materials) with or without bone grafts has also been extensively evaluated to assist in preserving alveolar ridge post tooth extraction (Mardas *et al.*, 2010; Avila *et al.*, 2014). Membrane exposure is considered to be detrimental in these procedures because it increases the risk of infection and disturbs bone formation; therefore, in the context of alveolar ridge preservation, a membrane that can be that can leave exposure to oral cavity and one that do not interfere with bone formation can be useful.

It is important to highlight that the above pre-clinical and clinical studies supporting these alveolar ridge preservation techniques are all based on single tooth extractions and an intact extraction socket. Few studies have reported alveolar ridge preservation techniques in damaged extraction sockets (missing one or more bony walls), which can frequently occur due to periodontal and endodontic problems. In one study, one hundred patients who had at least one tooth with one or more missing bony walls (damaged extraction socket) were studied following placement of either deproteinized bovine (DBBM) or porcine bone mineral (DPBM) for alveolar ridge regeneration (Lee *et al.*, 2018). The authors found comparable hard tissue augmentation with minimal reductions in the grafted volume at 4 months after surgery. A case series analysis of 20 patients with damaged sockets, who underwent an alveolar ridge preservation procedure using an open dense polytetrafluoroethylene membrane technique in combination with allografts, found that this technique allowed the placement of dental implants in all regenerated sites (Cheon *et al.*, 2017). An open-healing approach for sockets with bone deficiency has been tested and found that the use of a dense polytetrafluoroethylene (d-PTFE) membrane and freeze-dried allogenic bone substitute can be useful in alveolar ridge preservation and reduced horizontal bone resorption at 1 mm below the ridge crest in sockets with a bone deficiency (Sun *et al.*, 2019).

Therefore, the aim of this prospective case series analysis was to investigate the effect of alveolar ridge preservation on the residual alveolar ridge dimensions when using a bovine bone graft in association with a titanium foil in damaged extraction sockets at 6 months post-extraction.

Materials and Methods

Subject population

In total, 15 healthy subjects, 10 women and 5 men in the age-range from 18 to 65 years, with indications for tooth extraction and subsequent implant placement were enrolled in this case series analysis. These subjects received alveolar ridge preservation treatments at the Oral Implantology Clinic of Guarulhos University (Guarulhos, SP, Brazil) between January 2018 and October 2018. The study protocol was approved by the Guarulhos University Ethics Committee in Clinical Research (IRB: 61544116.7.0000.5506). The study protocol was explained to each subject, and patients who agreed to participate in the study signed the term of free and informed consent. All participants were prepared for surgery in accordance with accepted dental practice guidelines after appropriate demographic information and medical history data were collected.

Inclusion Criteria

All subjects were in good general health and had at least one tooth indicated for extraction and subsequent implant placement. The inclusion criteria were: aged between 18 and 70 years of age; anterior (incisor and canine) or posterior (pre-molar and molar) teeth; teeth presenting a buccal wall defect (damaged extraction sockets); a non-significant medical history and no current use of medications that might complicate results.

Exclusion Criteria

Subjects were excluded if they had a history of tobacco use within the last 6 months, healing disorders (i.e. diabetes mellitus, cancer, HIV, bone metabolic diseases), or had received systemic corticosteroids, immunosuppressive agents, radiation therapy, and/or chemotherapy within the past 6 months. Subjects taking intramuscular or intravenous bisphosphonates or who had allergies or sensitivity to alginate, latex, collagen or acrylic substances were also excluded; so were women who were pregnant, lactating or intending to become pregnant, or those participating in other clinical intervention studies.

Surgical Preservation Procedure

All subjects were treated by one trained and experienced dental surgeon (D.M.R). All patients received local anesthesia (Mepivalem Nova DFL, Rio de Janeiro, RJ, Brazil). One vertical incision in the mesial or distal region of the adjacent tooth was made with a 15c scalpel blade then the anterior or posterior teeth were carefully extracted using a periosteal elevator (Hu-Friedy instruments, Chicago, IL, USA). After this, a full thickness flap was raised and granulation tissue was removed. The extracted tooth alveoli were filled with a bovine bone substitute (Bionnovation Bonefill Porous Medium, Bauru, SP, Brazil).

According to the manufacturer, Bonefill Porous is a biphasic xenograft bone substitute consisting of bovine hydroxyapatite produced without any thermal process. The sockets were then covered with a non-resorbable anodized titanium membrane (Bionnovation Titanium Seal). According to the manufacturer, Titanium seal (Tseal) is a 0.04 mm thick nonporous titanium membrane, produced by an anodization process, with no electric charges. The titanium membrane was adapted and placed onto the buccal and lingual bone plate (4 mm below) and then the flap was sutured with 5-0 nylon sutures (Ethicon, Johnson & Johnson, São Paulo, Brazil), intentionally leaving the Tseal (Figure 1) exposed to the oral cavity.

Post-surgical Procedures

After surgery, all patients received 500 mg of amoxicillin (T.I.D for 7 days) and 750 mg Paracetamol (T.I.D. for 3 days) as well as 0.12% chlorhexidine digluconate solution (Periogard, São Paulo, SP, Brazil) for use twice a day for 14 days. In addition, all patients were instructed to discontinue tooth brushing in the surgical area during this period. Fourteen days after surgery, the sutures were removed and 21 days after surgery the titanium membrane was removed without local anesthesia. On the same day that the titanium membrane was removed, an interim fixed prosthesis was inserted, using acrylic teeth or the crowns of the extracted teeth. Special care was taken to avoid masticatory load in the grafted area. The patients were recalled for biofilm control and reinforcement of oral hygiene instructions monthly until 6 months after surgery.

Outcome Variables

One week before the surgery, cone-beam computerized tomography (CBCT) images were taken (T1—baseline; Figure 2a & b) using a plastic photographic retractor (Januario *et al.*, 2008). After 6 months, a second CBCT was taken (T2—6 months postoperative, (Figure 2a & b) as previously described. At baseline (T1) the distance between the palatal bone and the buccal aspect of the tooth was recorded. The same analysis was repeated at 6 months post-surgery and the distance between the palatal bone and the buccal bone wall was recorded at the same points. The measurements of the horizontal width of the alveolar socket (HW) to evaluate the distance between buccal and palatal bone distances, was always performed in the center of the alveolus (distance between the two lateral teeth), 1mm, 3mm and 5 mm above the palatal crestal bone (Primary outcome variable; Jung *et al.*, 2013), (Figure 2 a & b). In addition, in the tooth to be extracted the distance between the mesial and distal alveolar bone crest and one fixed point in an adjacent tooth (e.g., cemento-enamel junction, margin of a prosthesis) was determined at baseline (T1) and 6 months post-extraction (Figure 2c & d). A single calibrated (Kappa test > 90%) examiner evaluated the following tomographic parameters between baseline and 6 months post-surgery. All CBCT examinations were acquired by a scanner (model iCat Classic, Imaging Sciences International, LCC, Hatfield, PA, USA), with 0.25 mm slice thickness, reconstruction interval of 0.25 mm, and exposure factors of 120 KV and 36.12 mAs. To evaluate the reproducibility of the measurements (intra-observer) all samples were measured in duplicate and the differences were tested using intraclass correlation coefficient analysis (Spin-neto *et al.*, 2013). Data were stored in DICOM format and analyzed using the Ez3D Plus software (Vatech Global, Fort Lee, NJ, USA).

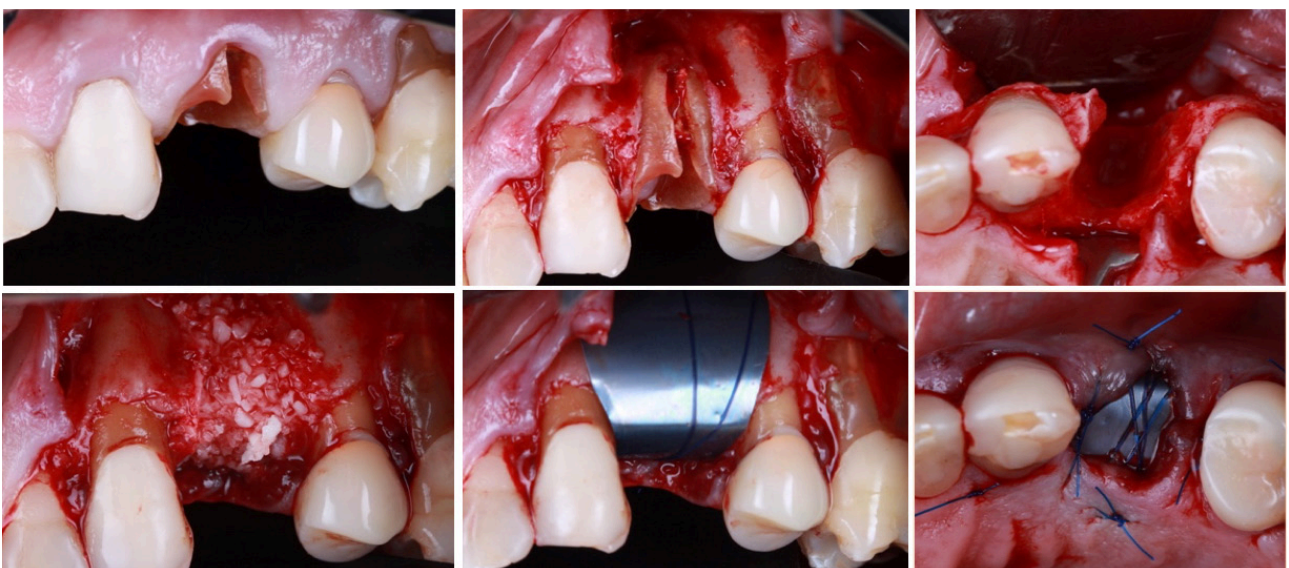


Figure 1. The titanium membrane was adapted and placed onto the buccal and lingual bone plate (4 mm below) and then the flap was sutured intentionally leaving the Tseal exposed to the oral cavity.

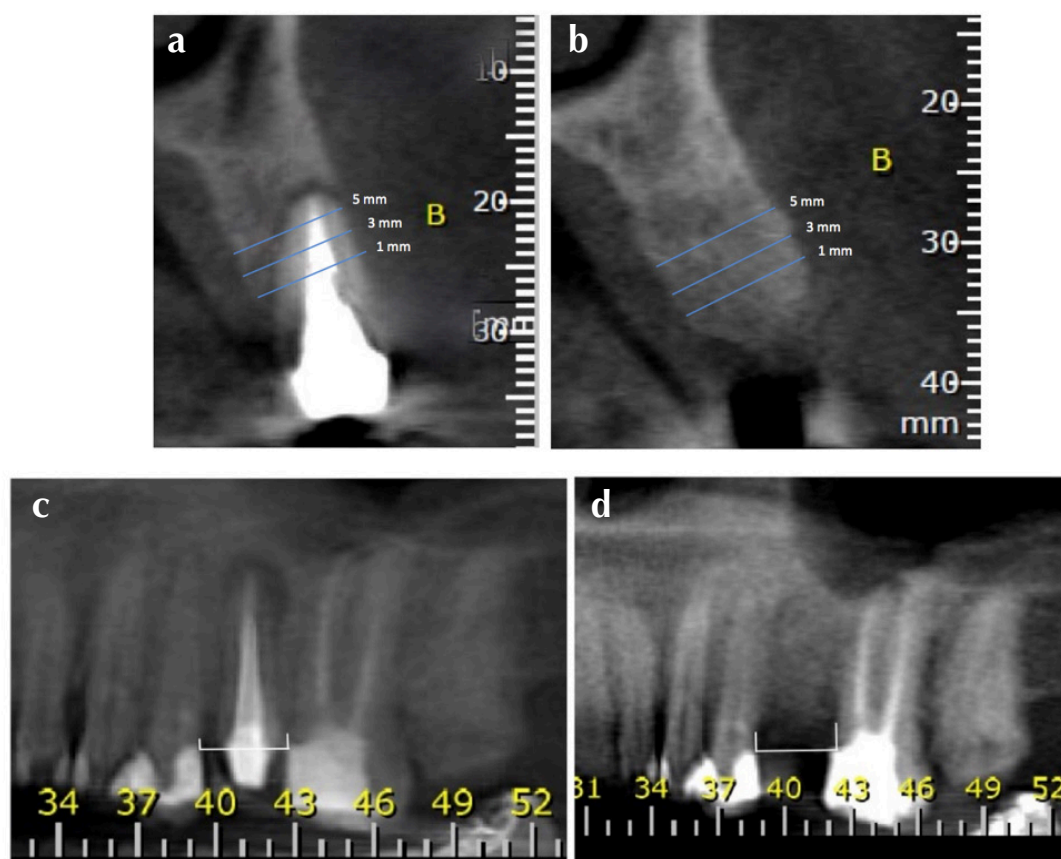


Figure 2. Cone-beam computerized tomography (CBCT) images taken at baseline (A&B). For the tooth to be extracted, the distance between the mesial and distal alveolar bone crest and one fixed point in an adjacent tooth (e.g., cemento-enamel junction, margin of a prosthesis) was determined at baseline (T1) and 6 months post-extraction (C & D).

Statistical Analysis

The mean value of HW (mm) at baseline and 6 months post-extraction, and the mean change between time points were computed for each subject and then averaged across subjects. The percentage of mean changes between time points were also evaluated. The Wilcoxon test was used to detect statistically significant differences between the two time points. The level of significance was set at 5%.

Results

Fifteen patients participated throughout the entire study period and met all the inclusion criteria according to the established protocol for this case series analysis. A list of the extracted teeth is present in Table 1. No postoperative complications were reported by any of the patients or observed by the operator during the experimental period. All patients removed the titanium foil at 21 days post-surgery without any pain.

Twelve maxillary teeth and three mandibular teeth were selected for this clinical study. Imaging assessment of HW presented an increase and decrease value in 09 and 06 subjects, respectively. The mean changes between baseline and 6 months post-surgery at 1mm, 3 mm and 5 mm points of analysis are shown in Figure 3. An

Table 1: Demographic data of the clinical study.

Subject	Tooth*	Gender	Age
1	24	Female	45
2	24	Female	61
3	11	Female	62
4	21	Female	64
5	13	Female	18
6	37	Female	56
7	41	Female	45
8	15	Male	65
9	16	Male	65
10	26	Male	65
11	16	Female	34
12	26	Female	30
13	22	Male	43
14	11	Male	43
15	12	Female	40

* FDI World Dental Federation notation

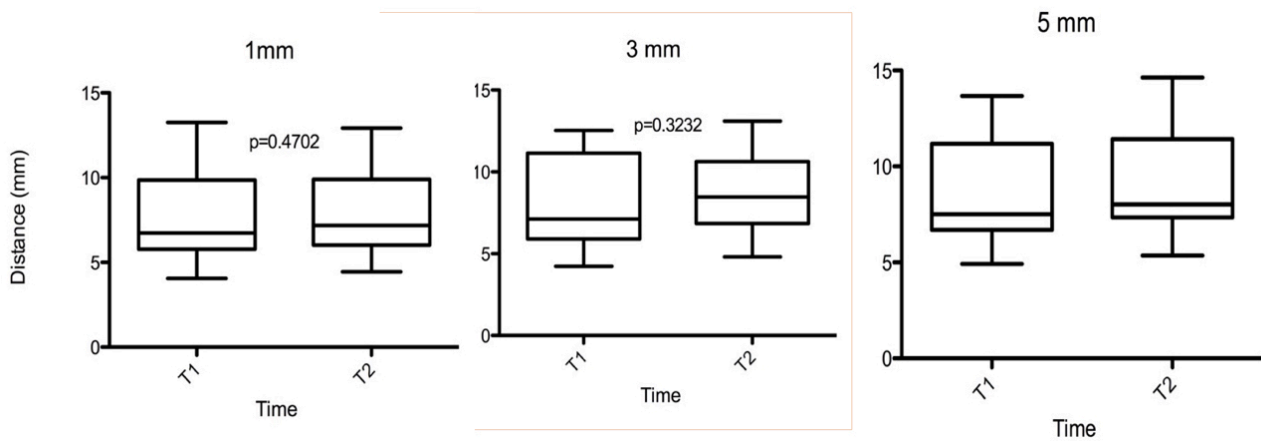


Figure 3. The mean changes between baseline and 6 months post-surgery at 1mm, 3 mm and 5 mm points of analysis.

Intergroup analysis showed no statistically significant differences between baseline and the 6 months in the linear evaluation at 1 mm, 3 mm and 5 mm areas of analysis. The average HW varied from 7.82 ± 2.75 mm (T1) to 8.02 ± 2.43 mm (T2) at 1 mm, from 7.99 ± 2.67 mm to 8.71 ± 2.26 mm at 3 mm and from 8.56 ± 2.60 mm to 9.00 ± 2.52 mm at 5 mm above the palatal bone crest. The mean distance between the palatal bone and the buccal aspect of the tooth increase between 0.19 ± 1.0 mm, 0.72 ± 1.0 and 0.44 ± 0.7 at 1, 3- and 5-mm distance, respectively. The mean proportion changes between baseline and 6 months post-surgery at 1mm, 3 mm and 5 mm points of analysis is shown in Figure 4. This procedure increased the distance between the palatal bone and the buccal wall of the tooth by 4%, 12% and 6%, at 1 mm, 3mm and 5 mm analysis, respectively. On an average this alveolar regeneration technique achieved 100% of the distance of the buccal and palatal/lingual wall after tooth extraction.

The mean values of the absolute rate and percentage of change in the mesial and distal interproximal bone crest height are shown in Figures 5 and 6. An Intergroup analysis showed no statistically significant differences between baseline and the 6 months evaluation (Figure 5). On an average this treatment protocol achieved

94% and 96% preservation in the mesial and distal interproximal bone crest height, respectively (Figure 6). No differences were observed between mesial and distal bone preservation ($p>0.05$).

Discussion

This case series analysis aimed to understand a ridge preservation approach in sockets with a severe buccal wall dehiscence defects using the titanium foil GBR concept. Few studies up to date have been focused on this type of alveolar socket (Lee *et al.*, 2015; Koutouzis and Lipton, 2016; Scheyer *et al.*, 2016; Cheon *et al.*, 2017; Lee *et al.*, 2018, Sun *et al.* 2018). Since bone remodeling and soft tissue collapse and their interference in bone healing are very common in these types of defects, they provide a critical methodological test. Therefore, we used the buccal wall of the extracted teeth as a guide for the purpose of quantifying the changes that occur in this type of defect. The healing process differs between intact or damaged extraction sockets. In intact extraction sockets, the mean change in the buccolingual dimensional in the coronal portion of the socket was 35% (Araujo and Lindhe, 2009a). For damaged extraction sockets the mean reduction was two times more severe (Lee *et al.*, 2015). The results showed that on an

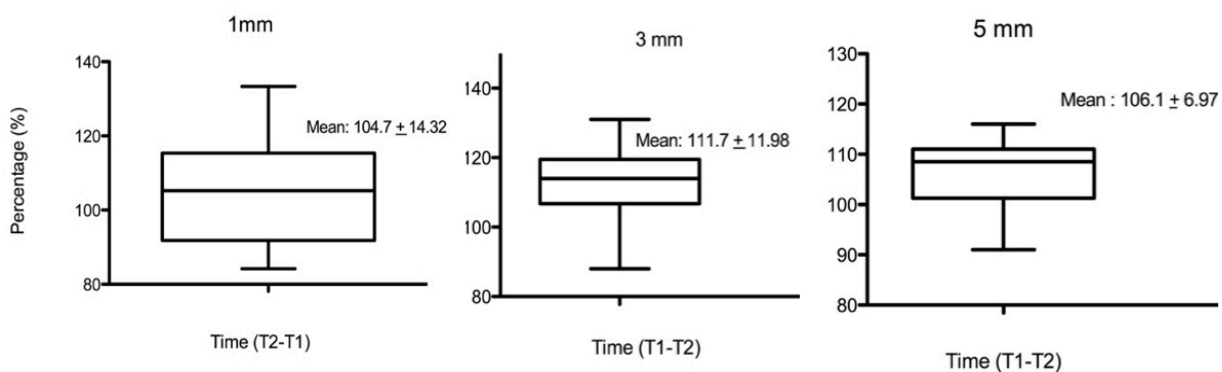


Figure 4. The mean proportion changes between baseline and 6 months post-surgery at 1mm, 3 mm and 5 mm points of analysis

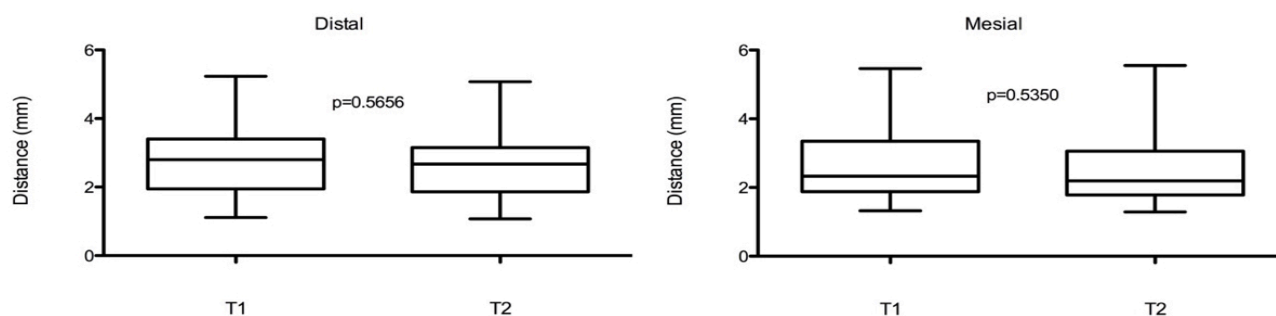


Figure 5 The mean values of the absolute rate of change in the mesial and distal interproximal bone crest height - An Intergroup analysis

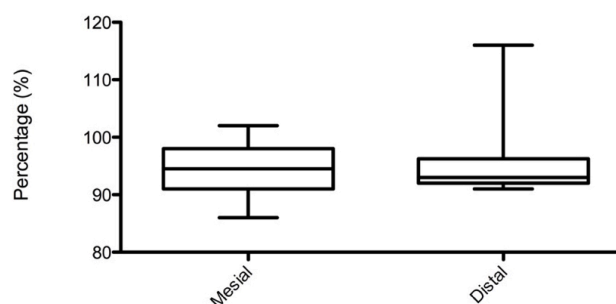


Figure 6. The mean values of the percentage of change in the mesial and distal interproximal bone crest height

average this alveolar regeneration approach maintained around 100% of the distance between palatal bone crest and buccal tooth wall (buccolingual dimensional) at 6 months post-surgery.

For the primary outcome variable of this study, the amount of horizontal ridge regeneration was considered good in all cases. Nine of 15 cases showed an increase in the linear measurement between bone crest and tooth wall at 6 months post-extraction, on an average the amount of their increase was around 14.8 % of the baseline measurement. Whereas 6 teeth lost some volume during healing period. At 6 months post alveolar preservation, the mean linear distance between buccal and palatal bone wall was 8.02 ± 2.75 mm. Clinically, all implants could be placed in all study sites.

The data from our study are in agreement with other studies that aimed to study ridge preservation after using a bone substitute and a membrane were to regenerate damaged alveolar sockets immediately after tooth extraction (Lee *et al.*, 2015; Koutouzis *et al.*, 2016; Scheyer *et al.*, 2016; Cheon *et al.*, 2017; Lee *et al.*, 2018). A randomized clinical trial studying the dimensional change in the alveolar ridge after the use of deproteinized bovine versus porcine bone mineral in damaged sockets in association with a collagen membrane reported comparable soft and hard tissue augmentation (Lee *et al.*, 2018). After 4 months post-surgery, minimal reduction in the grafted

volume, and in the horizontal and vertical dimensional. In fact, the bovine graft showed 1.83 ± 2.85 mm and porcine graft, 1.22 ± 2.16 mm, with similar reduction in horizontal dimensional at 4 months post-extraction (Lee *et al.*, 2018). In another study a very similar alveolar ridge preservation technique was reported using allograft bone graft in association with a high-density polytetrafluoroethylene (dPTFE) membrane in an “open membrane technique” in damaged extraction sockets (Cheon *et al.*, 2017). The dPTFE membrane was removed after 4 weeks. Histomorphometric analysis found that the mean area of new bone was around 28%, the remaining graft particle was 27% and there was 43 % of fibrous tissue at 4 months post-extraction. The authors concluded that this alveolar ridge preservation approach may be an appropriate technique for damaged sockets. In addition to these studies, we also analyzed the mean loss of marginal bone in the mesial and distal areas. Our results showed that minimal changes occurred in the interproximal bone crest, very similar to the data reported by Cheon *et al.* (2017), who found a change of 0.13 ± 0.06 mm in the mesial area and 0.15 ± 0.06 mm in the distal area. Therefore, the data found in our study were similar and even better than those cited, showing that the combination of the bovine mineral graft and Tseal used here showed good results when compared with those cited in the previous literature.

Despite the good clinical results, the present study had some limitations. This was a case series analysis; and a randomized clinical trial with a large number of subjects should be conducted in order to confirm these results. It could also be argued that even more groups would need to be tested, such as the combination of bovine bone graft in an open or closed membrane approach. In addition, no soft tissue measurements were done and some protocol issues such as intentional membrane exposure via socket entrance and healing time for implant placement should be evaluated in further studies. Therefore, this case clinical analysis should be interpreted conservatively, as a pilot study for the extended indication of extraction sockets grafting.

Conclusion

In conclusion, the application of bovine bone graft to a damaged extraction socket, covered with a Tseal resulted in substantial horizontal width preservation after tooth extraction. Further studies could be designed based on this study.

Disclosure

We declare that there are no conflicts of interests for any author in the present paper.

References

- Amler MH. The time sequence of tissue regeneration in human extraction. *Oral Surgery, Oral Medicine, Oral Pathology* 1969; **27**:309–318.
- Anwandter A, Bohmann S, Nally M, Castro AB, Quirynen M, and Pinto N. Dimensional changes of the post extraction alveolar ridge, preserved with Leukocyte- and Platelet Rich Fibrin: A clinical pilot study. *Journal of Dentistry* 2016; **52**:23–29.
- Araújo M, and Lindhe J. Dimensional ridge alterations following tooth extraction. *Journal of Clinical Periodontology* 2005; **32**:212–218.
- Araújo M and Lindhe J. Ridge alterations following tooth extraction with and without flap elevation: an experimental study in the dog. *Clinical Oral Implants Research* 2009a; **20**:545–549.
- Araújo M and Lindhe J. Ridge preservation with the use of Bio-Oss collagen: A 6-month study in the dog. *Clinical Oral Implants Research* 2009b; **20**:433–440.
- Ashman A. Postextraction ridge preservation using a synthetic alloplast. *Implant Dentistry* 2000; **9**:168–176.
- Avila-Ortiz G, Rodriguez JC, Rudek I, Benavides E, Rios H and Wang HL. Effectiveness of three different alveolar ridge preservation techniques: a pilot randomized controlled trial. *The International Journal of Periodontics & Restorative Dentistry* 2014; **34**:509–521.
- Beck TM, and Mealey BL. Histologic Analysis of Healing After Tooth Extraction With Ridge Preservation Using Mineralized Human Bone Allograft. *Journal of Periodontology* 2010; **81**:1765–1772.
- Becker W, Becker BE and Caffesse RA comparison of demineralized freeze-dried bone and autologous bone to induce bone formation in human extraction sockets. *Journal of Periodontology* 1994; **65**:1128–1133.
- Bianchini MA, Buttendorf AR, Benfatti CAM., Bez LV, Ferreira CF and de Andrade RF. The use of freeze-dried bone allograft as an alternative to autogenous bone graft in the atrophic maxilla: a 3-year clinical follow-up. *The International Journal of Periodontics & Restorative Dentistry* 2009; **29**:643–647.
- Cardaropoli G, Araújo M and Lindhe J. Dynamics of bone tissue formation in tooth extraction sites: An experimental study in dogs. *Journal of Clinical Periodontology* 2003; **30**:809–818.
- Cheon GB, Kang KL, Yoo MK, Yu JA, and Lee D. Alveolar Ridge Preservation Using Allografts and Dense Polytetrafluoroethylene Membranes With Open Membrane Technique in Unhealthy Extraction Socket. *The Journal of Oral Implantology* 2017; **43**:267–273.
- Clark D, Rajendran Y, Paydar S, et al. Advanced platelet-rich fibrin and freeze-dried bone allograft for ridge preservation: A randomized controlled clinical trial. *Journal of Periodontology* 2018; **89**:379–387.
- De Risi V, Clementini M, Vittorini G, Mannocci A and De Sanctis M. Alveolar ridge preservation techniques: a systematic review and meta-analysis of histological and histomorphometrical data. *Clinical Oral Implants Research* 2015; **26**:50–68.
- Froum S, Cho SC, Rosenberg E, Rohrer M and Tarnow D. Histological comparison of healing extraction sockets implanted with bioactive glass or demineralized freeze-dried bone allograft: a pilot study. *Journal of Periodontology* 2002; **73**:94–102.
- Horváth A, Mardas N, Mezzomo LA, Needleman IG and Donos N. Alveolar ridge preservation a systematic review. *Clinical Oral Investigations* 2013; **17**:341–363.
- Jung RE, Philipp A, Annen BM, et al. Radiographic evaluation of different techniques for ridge preservation after tooth extraction: a randomized controlled. *Clinical Oral Investigations* 2013; **17**:341–363.
- Koutouzis T and Lipton D. Regenerative needs following alveolar ridge preservation procedures in compromised and noncompromised extraction Sockets: A cone beam computed tomography study. *The International Journal of Oral & Maxillofacial Implants* 2016; **31**:849–854.
- Lee JS, Jung JS, Im GI, Kim BS, Cho K.S and Kim CS. Ridge regeneration of damaged extraction sockets using rhBMP-2: an experimental study in canine. *Journal of Clinical Periodontology* 2015; **42**:678–687.

- Lee JS, Cha JK and Kim CS. Alveolar ridge regeneration of damaged extraction sockets using deproteinized porcine versus bovine bone minerals: A randomized clinical trial. *Clinical Implant Dentistry and Related Research* 2018; **20**:729–737.
- Mardas N, Chadha V and Donos N. Alveolar ridge preservation with guided bone regeneration and a synthetic bone substitute or a bovine-derived xenograft: A randomized, controlled clinical trial. *Clinical Oral Implants Research* 2010; **21**:688–698.
- Scheyer ET, Heard R, Janakievski J, *et al.* randomized, controlled, multicentre clinical trial of post-extraction alveolar ridge preservation. *Journal of Clinical Periodontology* 2016; **43**:1188–1199.
- Schropp L. Bone healing and soft tissue contour changes following single- tooth extraction: A clinical and radiographic 12-month prospective study. *The International Journal of Periodontics & Restorative Dentistry* 2003; **23**:313–323.
- Sun DJ, Lim HC, Lee DW. Alveolar ridge preservation using an open membrane approach for sockets with bone deficiency: A randomized controlled clinical trial. *Clin Implant Dent Relat Res.* 2019; **21**:175–182.
- Spin-Neto R, Landazuri Del Barrio RA, Pereira L., Marcantonio R., Marcantonio E and Marcantonio E. Clinical similarities and histological diversity comparing fresh frozen onlay bone blocks allografts and autografts in human maxillary reconstruction. *Clinical Implant Dentistry and Related Research* 2013; **15**:490–497.
- Tan WL, Wong T, Wong M, and Lang NP. A systematic review of post-extraction alveolar hard and soft tissue dimensional changes in humans. *Clinical Oral Implants Research* 2012; **23**:1–21.
- Temmerman A, Vandessel J, Castro A, *et al.* The use of leucocyte and platelet-rich fibrin in socket management and ridge preservation: a split-mouth, randomized, controlled clinical trial. *Journal of Clinical Periodontology* 2016; **43**:990–999.
- Ten Heggeler J, Slot DE and Van der Weijden GA. Effect of socket preservation therapies following tooth extraction in non-molar regions in humans: a systematic review. *Clinical Oral Implants Research* 2011; **22**:779–788.
- Vignoletti F, Matesanz P, Rodrigo D, Figuero E, Martin C and Sanz M. Surgical protocols for ridge preservation after tooth extraction. A systematic review. *Clinical Oral Implants Research* 2012; **23**:22–38.
- Vittorini Orgeas G, Clementini M, De Risi V and de Sanctis M. Surgical techniques for alveolar socket preservation: a systematic review. *The International Journal of Oral & Maxillofacial Implants* 2013; **28**:1049–1061.